



## Ultrasound in the Sars-Cov-2 Pandemic: Summary of Applications, Advantages, and Limitations

---

Fellipe Silva, Tiago Dourado, Andre Alvarenga, Wagner Pereira and Rodrigo Costa-Felix

EasyChair preprints are intended for rapid dissemination of research results and are integrated with the rest of EasyChair.

February 19, 2023

# ULTRASOUND IN THE SARS-COV-2 PANDEMIC: SUMMARY OF APPLICATIONS, ADVANTAGES, AND LIMITATIONS

Fellipe A.M. Silva<sup>1</sup>, Tiago C. Dourado<sup>2</sup>, André V. Alvarenga<sup>2</sup>, Wagner C. A. Pereira<sup>1</sup>, Rodrigo P.B. Costa-Felix<sup>2</sup>

<sup>1</sup> Biomedical Engineering Program/COPPE/UFRJ, Rio de Janeiro, Brasil

<sup>2</sup> Laboratory of Ultrasound/Inmetro, Duque de Caxias, Rio de Janeiro, Brasil

**Abstract** — COVID-19 is caused by the coronavirus 2 (SARS-Cov-2). It may promote severe acute respiratory distress syndrome (ARDS), pneumonia and hypoxemia. Ultrasonography has been used for decades to detect biological tissue abnormality, although its B-mode imaging has only recently been used in lung exams. This paper aims to report documents related to the use of ultrasound as a tool to evaluate COVID-19 during the first pandemic year. Lung ultrasound is an essential tool for an early and reliable way to diagnose lung symptoms of respiratory diseases and for patients' follow-up.

**Keywords** — COVID-19; SARS-CoV-2; ARDS; lung ultrasonography; ultrasound imaging.

## I. INTRODUCTION

A Public Health Emergency of International Concern (PHEIC) was officially declared by the World Health Organization (WHO) on January 30<sup>th</sup>, 2020. The so-called COVID-19 is caused by the severe acute respiratory syndrome coronavirus 2 (SARS-Cov-2).

SARS-CoV-2 infected more than millions worldwide, with many presenting respiratory symptoms as a disease casualty. Complicated pneumonia cases may result in severe hypoxemia associated with low lung compliance, defined as acute respiratory distress syndrome (ARDS) [1].

COVID-19 was identified and spread initially in Wuhan, Hubei province, China, in late 2019. The disease was defined as a respiratory syndrome liable to lead to pulmonary commitment; after that, hypoxemia and pneumonia would result from COVID-19. Accurate diagnosis, provided as early as possible and preferably with minimum transportation of patients from and to health care centres, would be highly convenient. In a review of COVID-19 patients, about 20% of the studied cases required hospitalization in an intensive care unit (ICU), whilst about 33% presented ARDS.

Ultrasound B-mode imaging has been used for decades to detect biological tissue abnormality. Every tissue has its typical echogenicity and overall ultrasonographic

appearance, disclosing good correlation to its anatomy. Lung ultrasonography (LUS) has recently been considered a potential simple, fast, and reliable test to be applied for COVID-19 diagnostics (Fig 1). Nonetheless, proper image resolution and correct transducer choice are needed for an accurate evaluation and decision-making [2].

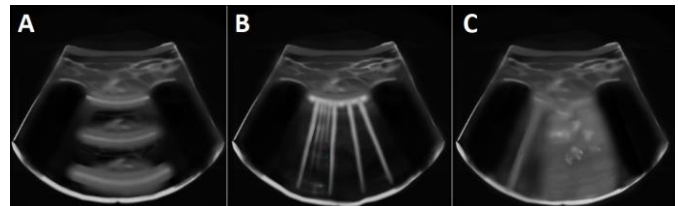


Fig 1: Images of lung ultrasonography. From the top-to-bottom of each image: skin layer, the muscle layer, and a hyperechoic pleural line on the edge of the lung surface. A) A-lines image. Health lung. B) B-lines image. Lung with water (more B-lines mean more parenchymal water). C) Lung consolidation image. Loss of pleural line continuity, coalescent B-lines and hyperechoic air bronchograms in consolidation areas can be seen in deflated lungs. Source: Graphic representation prepared by the authors.

This paper discloses a summary of applications, advantages, and limitations of LUS to detect ARDS due to COVID-19 for the lay biomedical engineering audience on this subject. The findings were obtained from a scoping literature review from Nov 2019 to May 2022.

## II. MATERIALS AND METHODS

The databases explored were Scopus, Web of Science and Pubmed Central.

The research strategy comprised the use of the following terms:

- T1. (ultraso\*) AND (coronav\*) AND (pneum\*)
- T2. (ultraso\*) AND (covid\*) AND (lung\*)
- T3. (ultraso\*) AND (covid\*) AND (lung\*) AND (pneum\*)
- T4. (ultraso\*) AND (coronav\*) AND (lung\*) AND (pneum\*)

After the document retrieval (289 articles), 40 were selected by title relevance. Following, 9 of them were chosen by critical analysis. They were undertaken as the most relevant documents to this review, and their main findings or outcomes were discussed.

### III. RESULTS AND DISCUSSION

The first records recommending the use of ultrasound in diagnosing COVID-19 came from researchers working at a medical referral centre in Sichuan province. For example, Pan et al. [3] highlighted the advantage of reducing cross-contamination probability with ultrasound concerning other imaging resources since the portability of the equipment minimized patient displacement.

Moro et al. [4] presented how to employ LUS in the guidance of obstetricians and gynaecologists in cases of pulmonary infection caused by COVID-19 in pregnant women. The application of imaging under non-ionizing radiation was the main highlight in the confrontation of SARS-CoV-2.

Stone 2020 [5] discussed how portable ultrasound imaging equipment could be used to assess pleural wall thickness and areas of pulmonary congestion, typical of pneumonia and that may suggest COVID-19. Concerning the post-examination, he highlighted that one of the advantages is the possibility of rapid disinfection, in addition to being used at the patient's bedside, unlike other methods that involve disinfecting entire rooms.

Baker and Rippey [6] point out some concerns about LUS as a diagnosis tool for COVID-19. Ultrasound may help with diagnosis, but it does not replace clinical signs and golden standards exams such as CT and RT-PCR. LUS results are not specific findings and require long training before proper application, as learning during a pandemic is not recommended. Additionally, Baker (2020) reported concerns about using LUS as a diagnostic tool for COVID-19. She reported that LUS results are neither specific nor direct findings, requiring training before proper application.

The idea of applying technological resources of artificial intelligence was also started in the first months of the pandemic. Dr Libertario Demi, head of the Ultrasound Laboratory at the University of Trento, Italy, engaged with collaborators from several hospitals in Italy. It developed algorithms that can assist in the interpretation of ultrasound images, with support for a database with more than 60,000 images obtained from patients with Covid-19 [7].

The works by Hussain et al. [8] and Evans et al. [9] discussed the importance of using robotic and remotely

operated ultrasonic systems capable of diagnosing the infection caused by the new coronavirus. Among the benefits, these studies report the great applicability of these resources in low- and middle-income countries that do not have a medical infrastructure for computed tomography, especially in places far from large population centres.

### IV. CONCLUSIONS

As mentioned by several authors, the use of LUS played a prominent role in diagnosing and monitoring patients who arrived at health centers for diagnosis and investigating the evolution of the new coronavirus. It can be noted that the classic advantages of this tool supported the recommendation of its use since the beginning of the pandemic. It is expected in the Biomedical Engineering field that both the improvement of image processing techniques, mainly in real-time, and the automation procedures that imply the creation of portable products, where wireless sensors have already been observed, allow the expansion of their applications.

### REFERENCES

1. Bernard GR, Artigas A, Brigham KL et al (1994). The American-European Consensus Conference on ARDS: definitions, mechanisms, relevant outcomes, and clinical trial coordination. *Am J Respir Crit Care Med.* 1994; 149(3 pt 1):818-824.
2. Corradi et al. (2020). Lung ultrasound and B lines quantification inaccuracy: B sure to have the right solution. *Intensive Care Med.* <https://doi.org/10.1007/s00134-020-06005-6>
3. Pan L, Wang L, Huang X (2020). How to face the novel coronavirus infection during the 2019–2020 epidemic: the experience of Sichuan Provincial People's Hospital. *Intensive Care Med* 46, 573–575, 2020. <https://doi.org/10.1007/s00134-020-05964-0>
4. Moro et al. *Ultrasound in Obstetrics & Gynecology* 55, p593, 2020.
5. Stone M. VIDEO: Imaging COVID-19 With Point-of-Care Ultrasound (POCUS). <https://www.itnonline.com/videos/video-imaging-covid-19-point-care-ultrasound-pocus>. Accessed on May 22nd, 2020.
6. Baker, K. and Rippey, J. *Australasian Journal of Ultrasound in Medicine* 23 p159, 2020
7. Davenport L (2020). Pulmonary ultrasonography may help the screening of patients with COVID-19 (in Portuguese). URL: <https://portugues.medscape.com/verartigo/6504637>. Accessed on May 22nd 2020.
8. Hussain, A., Via, G., Melniker, L. et al. Multi-organ point-of-care ultrasound for COVID-19 (PoCUS4COVID): international expert consensus. *Crit Care* 24, 702 (2020). <https://doi.org/10.1186/s13054-020-03369-5>.
9. Evans KD, Yang Q, Liu Y, Ye R, Peng, C. Sonography of the Lungs: Diagnosis and Surveillance of Patients With COVID-19 (2020) *Journal of Diagnostic Medical Sonography*. <https://doi.org/10.1177/8756479320917107>.